

Clinical Image

Copyright © All rights are reserved by Buse Ayse Serin

A Recommendation in The Treatment of Anterior Dental Crossbite Of A Single Tooth in The Early Mixed Dentition Period

Buse Ayse Serin*

Department of Pediatric Dentistry, Turkey

*Corresponding author: Buse Ayse Serin, Cukurova University, Faculty of Dentistry, Department of Pediatric Dentistry, 01330, Adana, Turkey.

Received Date: January 18, 2019

Published Date: February 01, 2019

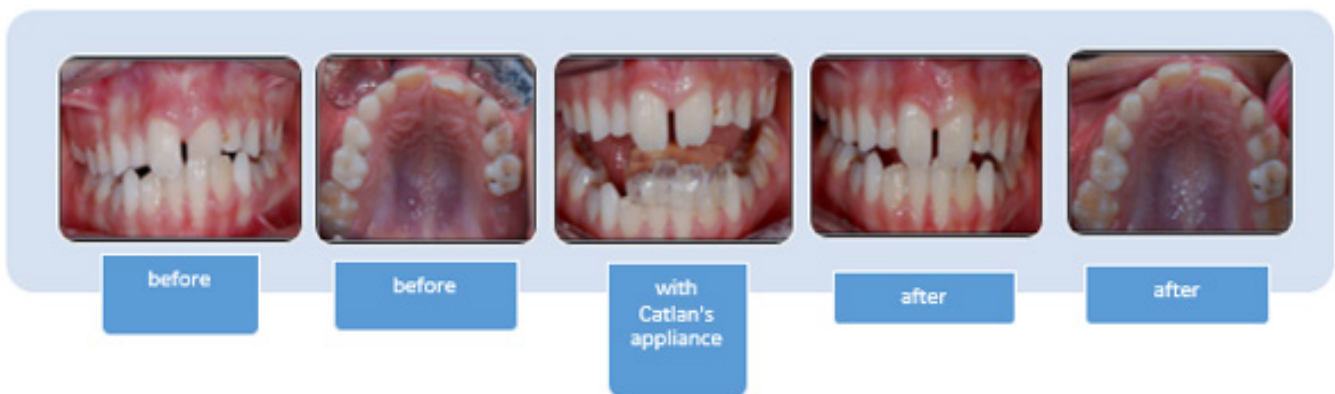
Clinical Image

Single tooth anterior dental crossbite can be esthetic and functional worrisome problem for parents and also for children during the development stage. Various treatment options such as removable and fixed appliances have been suggested, therewithal force to the immature teeth is a controversial issue among physicians.

This case presents a case of single tooth anterior dental crossbite corrected using the standard Catlan's appliance (Lower Inclined Bite Plane) in two weeks without any damage to the tooth

or the periodontium on the immature teeth and two year follow up until the completion of root development were presented. This fixed appliance is a simple and traditional method which does not depend on patient cooperation to reverse the bite.

With the early correction of the anterior cross-closure, the development of class 1 occlusion is supported, the traumatic occlusion of the anterior teeth is eliminated, the maxillary growth pattern is ensured and the child's self-confidence develops aesthetically.



Acknowledgment

None.

Conflict of Interest

Author declared no conflict of interest.