

Case Report

Copyright © All rights are reserved by Abid Awisat

# Crowned Dens

Abid Awisat<sup>1\*</sup> and Gleb slobodin<sup>1</sup>

Rheumatology unit, Bnai Zion Medical Center, Haifa, Israel

\*Corresponding author: Abid Awisat, Rheumatology unit, Bnai Zion Medical Center, Haifa, Israel.

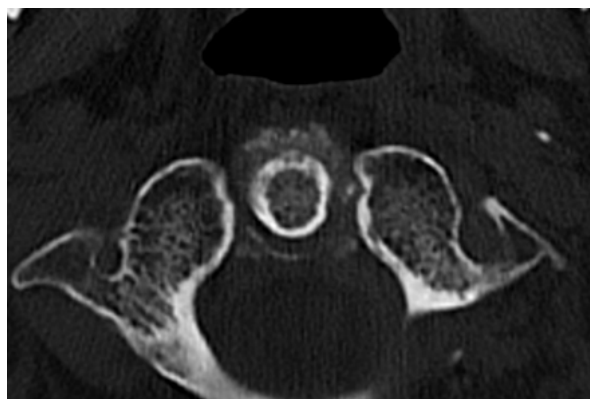
Received Date: July 29, 2022

Published Date: August 19, 2022

## Introduction

A 69 years old female was admitted to the emergency department with a three-day history of severe cervical pain and occipital headaches not responding to analgesics or non-steroidal anti-inflammatory drugs. Her medical history was unremarkable. Upon admission, she had a low-grade fever of 37.8C, and her physical examination demonstrated severe limitation of the cervical spine in all axes, with no neurological impairment. Blood workup revealed C-reactive protein 59 mg/L and erythrocyte

sedimentation rate of 94 mm/hour. Head computerized tomography (CT) showed picturesque extensive calcifications surrounding the dens in a circular pattern (Figure 1), compatible with Crowned dens syndrome (CDS). X-ray of peripheral joints demonstrated chondrocalcinosis in both knee joints compatible with calcium pyrophosphate depositions. The patient was started on prednisone 30 mg/d and colchicine 0.5 bid with rapid improvement of her complaints and restoration of cervical spine mobility.



**Figure 1:** Computerized tomography (CT) of C1-C2 section of cervical spine showing extensive, crown shaped calcifications surrounding the dens process (arrows).

CDS is defined as calcifications in the ligaments surrounding the odontoid process and aggravating acute cervical or occipital pain and stiffness, usually accompanied by elevated inflammatory markers [1,2]. High clinical suspicion is a prerequisite for the timely diagnosis of CDS, which is best confirmed by CT imaging, usually demonstrating faint punctate or linear deposits of calcium pyrophosphate within the transverse, alar, or apical ligaments.

Bulky calcium deposits, tightly enveloping the dens and forming the full crown as in the present report, and presumably related to calcium hydroxyapatite deposition, are rarely seen.

## Conflict of Interest

None.

## Acknowledgements

None.

## References

1. Bouvet JP, le Parc JM, Michalski B, Benlahrache C, Auquier L (1985) Acute neck pain due to calcifications surrounding the odontoid process: the crowned dens syndrome. *Arthritis Rheum* 28(12): 1417-1420.
2. Awisat A, Rosner I, Rimar D, Rozenbaum M, Boulman N, et al. (2020) Crowned dens syndrome, yet another rheumatic disease imposter. *Clin Rheumatol* 39(2): 571-574.